

Short report

Auditory hallucinations and brain structure
in schizophrenia: voxel-based morphometric study

Igor Nenadic, Stefan Smesny, Ralf G. M. Schlösser, Heinrich Sauer and Christian Gaser

Summary

We applied voxel-based morphometry to high-resolution magnetic resonance images of 99 participants with schizophrenia. Voxel-wise correlations with a score of auditory hallucination severity identified areas in the left and right superior temporal cortex (including Heschl's gyrus), left supramarginal/angular gyrus, left postcentral gyrus and left posterior cingulate cortex. This study extends previous

region-of-interest studies demonstrating main effects of auditory hallucinations related to modality-specific superior temporal areas including primary and secondary auditory cortices.

Declaration of interest

None.

Magnetic resonance imaging (MRI) studies of schizophrenia have delineated structurally compromised neural networks, including prefrontal, medial temporal and superior temporal cortices. In addition, studies using region-of-interest volumetry have identified correlations of superior temporal gyrus areas with symptoms including auditory hallucinations, thought disorder and cognitive deficits.¹ These studies, however, have been limited to particular areas of the superior temporal gyrus, such as the anterior gyrus or planum temporale, further complicated by diverging anatomical definitions of subregions. Voxel-based studies have mostly relied on small sample sizes and often compared either patients with persistent hallucinations and controls,^{2,3} or hallucinating and non-hallucinating patients.⁴ Only two smaller studies directly correlated measures of auditory hallucinations with temporal brain structural measures in participants with first-episode or chronic disorder.^{5,6} In this study we sought to extend our earlier findings of multifocal frontotemporal changes related to auditory hallucinations,⁷ by applying voxel-based morphometry (VBM) in a larger cohort of patients with schizophrenia to allow comparability with recent VBM studies in patients with auditory hallucinations.

Method

We analysed high-resolution images acquired on a 1.5T Philips ASCII MRI scanner (Philips Medical Systems, Best, The Netherlands): repetition time 13 ms, echo time 5 ms, flip angle 250, 256 sagittal slices, voxel dimensions 1 mm × 1 mm × 1 mm. Participants were 99 patients with schizophrenia (57 men and 42 women, aged 18–65 years, mean 36.2 years, s.d. = 11.2) treated at our department and diagnosed according to both ICD-10 and DSM-IV using semi-structured interviews. None of the patients had a second psychiatric, neurological or major medical condition, or history of traumatic brain injury. All participants were stable in terms of both medication and clinical symptoms before undergoing scanning and rating with the Scales for Assessment of Positive/Negative Symptoms (SAPS/SANS).⁸ The sample was partly based on a previously studied cohort of 85 patients.^{7,9} All patients gave written informed consent to a study protocol approved by the ethics committee of the University of Jena medical school. For MRI analysis we applied VBM2 (<http://dbm.neuro.uni-jena.de/vbm>), implemented as a toolbox in SPM (Institute of Neurology, London, UK), using hidden Markov random fields to increase the signal-to-noise ratio. Images were

segmented and normalised onto a previously created study-specific custom template. We computed an auditory hallucinations score as a sum of SAPS single items for auditory hallucinations: voices conversing and voices commenting. For statistics, we used a general linear model entering the auditory hallucinations score as a variable of interest (regressor) and removing effects of age, gender and SAPS total score (without auditory hallucinations) to obtain voxel-wise correlations of each cerebral grey matter voxel with auditory hallucination severity. Based on the previous findings and the resulting anatomical hypotheses, we applied an uncorrected height threshold of $P < 0.01$ as well as an extent threshold of $k = 723$ voxels (expected number of voxels according to random field theory).

Results

The distribution of hallucination scores is given in online Fig. DS1. Voxel-based analyses (Fig. 1) revealed six cortical (but no subcortical or cerebellar) clusters correlated with severity of auditory hallucination (maximum voxel coordinates and t -values in parentheses): left primary/secondary auditory cortex ($-58, -11, 9; t = 3.30$); left anterior superior temporal cortex ($-57, 3, -10; t = 3.82$); right superior temporal gyrus including the primary/secondary auditory cortex ($64, -19, 14; t = 3.75$) and

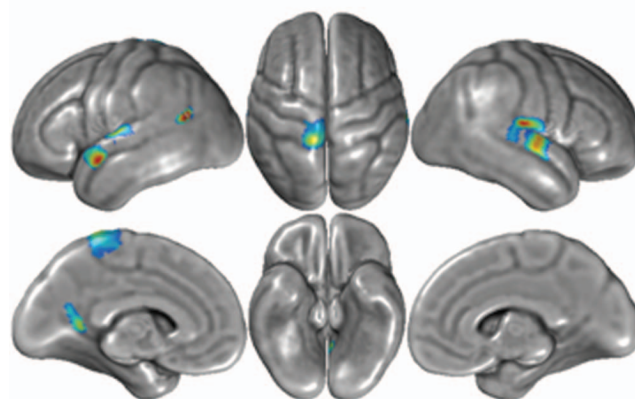


Fig. 1 Voxel-based morphometry analysis of voxel-wise correlations of grey matter with auditory hallucination severity score in the patient cohort. Significant results with $P < 0.01$ (uncorrected) and extent threshold $k = 723$ voxels are projected onto the cortical surface.

mid-superior temporal gyrus area (55, -14, 0; $t=3.53$); left angular gyrus (51, -51, 18; $t=4.18$); left postcentral gyrus (-12, -38, 75; $t=3.27$); and left posterior cingulate cortex extending towards the precuneus (-14, -53, 12; $t=3.16$).

Discussion

We found several temporal and parietal brain areas to be correlated with severity of auditory hallucinations in schizophrenia. This finding offers three important new insights. First, the superior temporal gyrus is affected bilaterally to different extents in specific subregions. Importantly, this includes the primary and secondary auditory areas, long suspected to be a modality-specific correlate of this symptom. These areas coincide with findings from functional MRI studies,¹⁰ as well as potential target areas of repetitive transcranial magnetic stimulation therapy for treatment-resistant auditory hallucinations.¹¹ To our best knowledge our study is the largest VBM study of its kind, and is thus likely to provide higher statistical power than previous studies of hallucinations in schizophrenia with smaller sample sizes. However, its cross-sectional nature precludes identification of the timing of these changes. A study of auditory hallucinations in bipolar disorder, in which this symptom is much less frequent, found a similar correlation for a slightly more inferior cluster in the middle temporal cortex.¹² Second, our findings suggest that this specific association of superior temporal/Heschl's gyrus alterations and auditory hallucinations is not categorical, but rather reflects an increasingly higher load of structural changes to be associated with symptom expression. This implies a dimensional rather than categorical association. Some previous MRI studies have been restricted to people with persistent auditory hallucinations,^{2,3} which gives some advantage for phenotypic stability. In contrast, our correlational approach takes into account patients with a low probability of having (or having had) auditory hallucinations and also those without current hallucinations. Considering other disease-related sources of variation, the findings are thus less likely to reflect changes due to selection of a subgroup of patients with schizophrenia in whom auditory hallucinations persist over longer periods or are treatment-refractory. Third, we found several areas outside the superior temporal gyrus to be correlated with auditory hallucinations as well. Although the inferior lateral parietal cluster (located somewhat posterior to a supramarginal cluster of our previous study) may be related to verbal aspects of hallucinations,⁷ we did not replicate our previous finding of right prefrontal changes. Also, the postcentral changes, although described in another VBM study of auditory hallucinations,² have not been included in any of the current hypotheses (either misattribution of inner speech or modality-specific sensory cortical dysfunction); hence, their significance remains unclear.

A few limitations should be considered. First, VBM does not disclose the nature of underlying neuropathological changes. Although reduction of neuropil would be a potential substrate, we cannot exclude effects of local cerebral blood volume or flow. As with most studies correlating a state-related variable (such as psychopathological symptoms) with a rather trait-related variable (such as brain structure), findings might be prone to type 2 errors, as symptoms are more dynamic than structural changes. However, it is important to note the stable psychopathological state of our patients, and that our superior temporal gyrus findings in particular are consistent with previous findings using region-of-interest or VBM methods.^{1,3,5} Also, we statistically removed

variance related to SAPS total score (without auditory hallucination items), which makes it less likely that results reflect significant correlations with positive symptoms overall. Finally, we need to consider the effect of antipsychotic medication, since we were not able to correct for lifetime antipsychotic exposure, which might vary in relation to symptom profiles.

Taken together, our findings provide refined anatomical mapping of auditory hallucinations in schizophrenia using the largest sample studied so far, and have identified a set of superior temporal cortical areas, including primary and secondary auditory cortex, which provide a modality-specific structural correlate of this frequent symptom of schizophrenia.

Igor Nenadic, MD, **Stefan Smesny**, MD, **Ralf G. M. Schlösser**, MD, PhD, **Heinrich Sauer**, MD, PhD, **Christian Gaser**, MEE, PhD, Department of Psychiatry and Psychotherapy, Friedrich Schiller University, Jena, Germany

Correspondence: Dr Igor Nenadic, Department of Psychiatry and Psychotherapy, Friedrich-Schiller-University of Jena, Philosophenweg 3, D-07743 Jena, Germany. Email: igor.nenadic@uni-jena.de

First received 7 Jul 2009, final revision 11 Nov 2009, accepted 21 Dec 2009

Funding

The study was supported by a Junior Scientist Grant (DRMF, 21007087) from the Friedrich-Schiller-University of Jena, Germany (to I.N.) and BMBF grants 01EV0709 and 01GW0740 (to C.G.).

References

- Sun J, Maller JJ, Guo L, Fitzgerald PB. Superior temporal gyrus volume change in schizophrenia: a review on region of interest volumetric studies. *Brain Res Rev* 2009; **61**: 14–32.
- Garcia-Marti G, Aguilar EJ, Lull JJ, Marti-Bonmati L, Escarti MJ, Manjon JV, et al. Schizophrenia with auditory hallucinations: a voxel-based morphometry study. *Prog Neuropsychopharmacol Biol Psychiatry* 2008; **32**: 72–80.
- O'Daly OG, Frangou S, Chitnis X, Shergill SS. Brain structural changes in schizophrenia patients with persistent hallucinations. *Psychiatry Res* 2007; **156**: 15–21.
- Shin SE, Lee JS, Kang MH, Kim CE, Bae JN, Jung G. Segmented volumes of cerebrum and cerebellum in first episode schizophrenia with auditory hallucinations. *Psychiatry Res* 2005; **138**: 33–42.
- Sumich A, Chitnis XA, Fannon DG, O'Ceallaigh S, Doku VC, Faldrowicz A, et al. Unreality symptoms and volumetric measures of Heschl's gyrus and planum temporal in first-episode psychosis. *Biol Psychiatry* 2005; **57**: 947–50.
- Lee K, Yoshida T, Kubicki M, Bouix S, Westin CF, Kindlmann G, et al. Increased diffusivity in superior temporal gyrus in patients with schizophrenia: a diffusion tensor imaging study. *Schizophr Res* 2009; **108**: 33–40.
- Gaser C, Nenadic I, Volz HP, Buchel C, Sauer H. Neuroanatomy of 'hearing voices': a frontotemporal brain structural abnormality associated with auditory hallucinations in schizophrenia. *Cereb Cortex* 2004; **14**: 91–6.
- Andreasen N. Methods for assessing positive and negative symptoms. *Mod Probl Pharmacopsychiatry* 1990; **24**: 73–88.
- Nenadic I, Sauer H, Gaser C. Distinct pattern of brain structural deficits in subsyndromes of schizophrenia delineated by psychopathology. *Neuroimage* 2010; **49**: 1153–60.
- Ford JM, Roach BJ, Jorgensen KW, Turner JA, Brown GG, Notestine R, et al. Tuning in to the voices: a multisite fMRI study of auditory hallucinations. *Schizophr Bull* 2009; **35**: 58–66.
- Hoffman RE, Hampson M, Wu K, Anderson AW, Gore JC, Buchanan RJ, et al. Probing the pathophysiology of auditory/verbal hallucinations by combining functional magnetic resonance imaging and transcranial magnetic stimulation. *Cereb Cortex* 2007; **17**: 2733–43.
- Stanfield AC, Moorhead TW, Job DE, McKirdy J, Sussmann JE, Hall J, et al. Structural abnormalities of ventrolateral and orbitofrontal cortex in patients with familial bipolar disorder. *Bipolar Disord* 2009; **11**: 135–44.

